

## Anomaly scan

### Document Information

<b>Document Type:</b>	Guideline														
<b>Valid From:</b>	07/06/2019														
<b>Date of Review:</b>	07/06/2022														
<b>Appraisal Score:</b>	<table border="1"> <thead> <tr> <th>Domain</th> <th>1</th> <th>2</th> <th>3</th> <th>4</th> <th>5</th> <th>Overall</th> </tr> </thead> <tbody> <tr> <td>Score (%)</td> <td>92</td> <td>84</td> <td>81</td> <td>81</td> <td>91</td> <td>84%</td> </tr> </tbody> </table>	Domain	1	2	3	4	5	Overall	Score (%)	92	84	81	81	91	84%
Domain	1	2	3	4	5	Overall									
Score (%)	92	84	81	81	91	84%									
<b>Ratification Date &amp; Body:</b>	26/04/2019 Maternity Clinical Governance Committee														
<b>Document Author(s):</b>	Consultant Obstetrician, Clinical Lead Ultrasound Consultant Obstetrician, Fetal Medicine and High Risk Pregnancy Lead														
<b>Development Group Member(s):</b>	Maternity Out-Patient Manager Lead Sonographer, Horton General Hospital SST Maternal and Fetal Medicine Antenatal Screening Coordinator AHSN Maternity Network Manager Associate Specialist in Fetal Cardiology Consultant Neonatologist, John Radcliffe Hospital.														
<b>Clinical Lead:</b>	Consultant Obstetrician														
<b>Associated OUH Documents:</b>	<a href="#">Referral when a fetal abnormality is detected</a> <a href="#">Growth Scan Guideline</a>														
<b>Document Replaces:</b>	Anomaly Scan v1.4, 24/05/2018 Anomaly Scan v.1.3, 23/03/2018 Anomaly Scan v.1.2, 09/11/2017 Anomaly Scan v1.1, 10/07/2017 Anomaly Scan v1.1, 03/05/2016														
<b>Equality Impact Assessment:</b>	26/03/2015														

## Contents

Background.....	3
Aims.....	3
Scope.....	3
Definitions.....	4
Executive Summary.....	5
Full guideline.....	6
<i>Pre-scan information.....</i>	<i>6</i>
<i>Consent.....</i>	<i>6</i>
<i>Measurements.....</i>	<i>6</i>
<i>Basic anatomical views to be assessed.....</i>	<i>6</i>
<i>Fetal cardiac scan.....</i>	<i>7</i>
<i>Uterine artery Doppler (NEW).....</i>	<i>8</i>
<i>What to do if anomaly scan cannot be completed.....</i>	<i>8</i>
<i>Image acquisition and storage.....</i>	<i>8</i>
<i>Detection of normal variants and markers that should be referred for further assessment (NEW).....</i>	<i>9</i>
<i>Placental localisation.....</i>	<i>9</i>
<i>Amniotic fluid.....</i>	<i>10</i>
<i>Outcomes of fetal anomaly scan- data entry, diagnosis fields and referrals.....</i>	<i>10</i>
<i>Outcome of risk assessment for small for gestational age/growth pathway.....</i>	<i>12</i>
<i>Further assessment of fetal size following the anomaly scan (NEW).....</i>	<i>13</i>
Appendix 1 – Overview of anatomical views to be assessed at the anomaly scan.....	15
Appendix 2 – Base menu of anatomical images to be stored.....	16
Appendix 3 – Fetal cardiac anomaly scan.....	21
Appendix 4 – Uterine artery Doppler.....	25
Appendix 5 – Placental site assessment.....	27
Appendix 6 – Monitoring and compliance.....	28
References.....	29
Further resources/training.....	29

## Background

The main objectives of the anomaly scan are to:

- Identify serious fetal abnormalities, either incompatible with life or associated with morbidity, to allow women to make informed choices.
- Identify certain abnormalities which may benefit from antenatal treatment.
- Identify certain abnormalities which require early intervention.
- Identify women at high risk of early onset impaired fetal growth

The scan should be offered to all women between 18+0 and 20+6 weeks.

## Aims

The aims of this guideline are to

- Outline the screening scan protocol
- Describe the pathway of care if an anomaly is suspected
- Outline the internal quality assurance arrangements

## Scope

This document is intended to provide practical guidance for all health care practitioners involved in the fetal anomaly screening pathway within OUH NHS Foundation Trust. Discussion relating to external quality assurance/governance is out with the remit of this local guideline.

## Definitions

Term	Definition
FASP	Fetal Anomaly Screening Programme
FMU/PND	Fetal Medicine Unit/Prenatal Diagnosis
EPR	Electronic Patient Records
AC	Abdominal circumference
CHD	Congenital heart disease
AP	Anteroposterior
Viewpoint	Software used to store scan examination data and to generate scan reports
TV	Transvaginal
AFI	Amniotic fluid index
PD	Pool depth
Ut Art	Uterine artery

## Executive Summary

- The fetal anomaly scan should be offered to all pregnant women and is usually performed between 18+0 and 20+6 weeks
- The aims of this scan are to
  - Identify serious fetal abnormalities, either incompatible with life or associated with morbidity, to allow women to make informed reproductive choices.
  - Identify certain abnormalities which may benefit from antenatal treatment.
  - Identify certain abnormalities which require early intervention following birth.
- The fetal anomaly scan is a screening test for major structural anomalies and as such, not all anomalies will be detected by this scan.
- Uterine artery Doppler is performed to aid risk assessment in all singleton pregnancies.
- Written consent should be obtained prior to the scan examination.
- The NHS Fetal Anomaly Screening Programme (FASP) has issued standards for this scan assessment which include a number of fetal views that should be assessed on each anomaly scan. In addition, NHS FASP has specified images that should be stored for each anomaly scan (basic anatomy and cardiac anatomy).
- If a scan cannot be completed at first attempt, the reasons for this should be documented on the report generated by Viewpoint, explained to the patient and a further scan no later than 23 weeks offered.
- In the event of suboptimal imaging of the heart at anomaly scan, this should be recorded on the newborn infant record (purple booklet) in the maternity hand held notes with the request to check neonatal oxygen saturations before discharge.
- Normal variations of fetal anatomy do not require review in the Fetal Medicine Unit.
- Abnormalities should be referred to the Fetal Medicine Unit.
- Where there is uncertainty, a request for Fetal medicine *scan* review may be made using the email address or faxed form.
- There is a separate pathway of care for women in whom a suspected fetal anomaly has been identified.

## Full guideline

### Pre-scan information

It is important that both women and health professionals appreciate that the scan is a screening test and because of that it has limitations. Inevitably, some conditions may be missed or misidentified. Women should receive comprehensive information before the scan in a language appropriate to them. The verbal offer of an anomaly scan is usually made by the woman's midwife. If a woman chooses to decline to have a fetal anomaly scan, this must be respected and her decision should be documented in her maternity notes and on EPR.

A full bladder is not required but do not ask her to empty her bladder unless it is impairing views because an empty bladder can make placental site assessment less accurate.

### Consent

Currently, written consent is gained when the woman attends for her anomaly scan. This is on the 'before your anomaly scan' section of the [Pregnancy Scan pathway sheet](#). This should be filed in her maternity notes.

### Measurements

The following measurements are requirements.

- Biparietal diameter
- Head circumference
- Ventricles
- Transcerebellar diameter
- Abdominal circumference
- Femur length
- Deepest vertical pool
- Uterine artery Doppler on both sides

All measurements should be transferred automatically by DICOM, not by entering them manually.

Press the display centiles button after entering measurements.

### Basic anatomical views to be assessed

The main structures that should be identified and assessed at the anomaly scan are outlined in Appendix 1. This assessment enables screening for a number of major conditions.

The national standards pertaining to the detection rates of these conditions are summarised in Table 1.

Table 1: Conditions that are screened as part of Fetal Anomaly Screening Protocol and anticipated detection rates (FASP, 2010).

Conditions	Detection rate
Anencephaly	98%
Open spina bifida	90%
Cleft lip	75%
Diaphragmatic hernia	60%
Gastroschisis	98%
Exomphalos	80%
Serious cardiac abnormalities	50%
Bilateral renal agenesis	84%
Lethal skeletal dysplasia	60%
Trisomy 13	95%
Trisomy 18	95%

Of these anatomical views assessed, the following 6 images should be stored at the time of the anomaly scan **as a minimum**:

1. Head circumference demonstrating head circumference and measurement of the atrium of lateral ventricle.
2. Suboccipito-bregmatic view of head demonstrating measurement of the transcerebellar diameter.
3. Coronal view of lips with nasal tip and both nostrils.
4. Abdominal circumference demonstrating AC measurement.
5. Sagittal view of dorsum of spine including sacrum and skin covering.
6. Femur length demonstrating femur length measurement.

These are illustrated in Appendix 2 together with schematic drawings of each view to illustrate key anatomical landmarks.

### Fetal cardiac scan

Congenital heart disease is defined for the purpose of anomaly scanning as a condition that will require immediate cardiac assessment at birth and/or treatment within the first year of a child's life.

As part of basic fetal echocardiography, situs/laterality, heart size, heart rate and rhythm must be examined. Fetal cardiac anomaly scanning should also assess:

1. Four chamber view of heart (4C)
2. Aorta/Left ventricular outflow tract (LVOT)
3. Pulmonary/Right ventricular outflow tract OR Three vessel (pulmonary artery, aorta, superior vena cava) view (RVOT)

#### 4. Three Vessel Trachea View (3VT)

Images of these four views must be stored - if storing still images, these should ideally be labelled as “4C”, “LVOT” or “RVOT” or 3VT. It is also acceptable to store a short cine loop of the cardiac examination as a transverse “sweep” (see Carvalho et al, 2013, for further information/useful tips on scanning technique).

Examining outflow tract increases detection rates for major cardiac malformations above those achievable by four chamber view alone. The inclusion of outflow tracts is more likely to identify conotruncal anomalies such as tetralogy of Fallot, transposition of the great arteries, double outlet right ventricle and truncus arteriosus.

A summary of the structures that require assessment and an overview of key features that should be assessed in each view are outlined in Appendix 3.

The use of colour flow Doppler is not a requirement at present but is encouraged as it may help provide additional information and improve detection of CHD.

An assessment of vessel number, size, alignment and arrangement can increase detection of certain anomalies that may have a normal four-chamber view including transposition of the great arteries, tetralogy of Fallot and pulmonary atresia with a ventricular septal defect. The 3VT, in assessing the relationship to the trachea is more likely to enable detection of lesions such as coarctation of the aorta, right aortic arch and double aortic arch (see also Cavalho JS et al, 2013).

#### **Uterine artery Doppler (NEW)**

These are assessed in every singleton pregnancy at the time of the anomaly scan (from 09/05/2016). Occasionally only one will be obtainable and this is usually because of an abnormal uterine shape. Please refer to Doppler Guideline in Appendix 4 for the technique.

#### **What to do if anomaly scan cannot be completed**

If a scan cannot be completed at first attempt, the reasons for this should be documented in the report generated on Viewpoint, explained to the woman and a further scan no later than 23 weeks be offered.

If the fetal cardiac scan cannot be adequately imaged even with the second scan, this should be explained to the woman and an entry should be made by the sonographer undertaking the exam, in the neonatal pages to the effect of

*“unable to complete fetal cardiac anomaly scan - please check neonatal oxygen saturations before discharge - if there are any concerns, the neonatal unit registrar should be informed”.*

#### **Image acquisition and storage**

The views outlined in preceding sections capture some of key anatomical areas that are screened for major anomalies. Images stored reflect the overall quality of the examination.

If there are factors during the examination that have made it more difficult to complete the scan and/or obtain good quality images to store, this should be clearly documented in the “Comments” section of the report generated on Viewpoint. Such factors might include obesity, body habitus, multiple uterine fibroids. This should also be explained tactfully to the woman.

Poor image documentation precludes the possibility for reinterpretation and could support allegations that an incomplete or inadequate study has been performed.

### Detection of normal variants and markers that should be referred for further assessment (NEW)

The term “soft marker” should no longer be used.

Table 2 lists normal variants that do **NOT** require referral to FMU.

#### **Table 2: Normal variants that should NOT be reported or referred**

Choroid plexus cyst(s)*
Echogenic foci in the heart without a structural abnormality
Two vessel cord

\*if there is ventricular enlargement >10mm in association with CPCs, refer to FMU.

Listed in Table 3 are examples of findings that should be reported and the woman referred to the Fetal Medicine Unit for further assessment and treated/investigated as for any other suspected fetal anomaly.

#### **Table 3: Findings that should be referred for further assessment**

Nuchal fold $\geq 6\text{mm}$
Ventriculomegaly $>10\text{mm}$
Cisterna Magna $>10\text{mm}$
Echogenic bowel (with density equivalent to bone)
Unilateral or bilateral renal pelvic dilation (AP measurement $>7\text{mm}$ )
Small measurements (See page 12, ‘Further assessment of fetal size following the anomaly scan’)

### Placental localisation

The placental site should be assessed as part of the anomaly scan and findings recorded using the appropriate dropdown box on the anomaly screen on Viewpoint.

If the placenta is low (i.e.  $<1\text{cm}$  from internal os) or under the uterovesical fold (UVF) (see Appendix 5) ask the woman if she has had a previous caesarean section or any other uterine surgery.

If there has been previous uterine surgery:

1. Anterior placenta not low but under the UVF AND previous CS – re-scan in the US dept at 28 weeks. If the placenta is still under the UVF refer to placenta clinic ASAP.
2. Anterior low placenta or placenta praevia at 20 weeks AND previous CS – refer to FMU placenta clinic where the women will be scanned at 28 weeks.

If there has not been previous uterine surgery:

- Whether it is under the UVF is not important.
- Record the placenta in Viewpoint as low if it is <1cm from internal os, but not if it is merely under the uterovesical fold.
- Do not book an extra scan: the routine 36 week scan will suffice.

Explain these findings to the woman and that she should attend hospital if she has any vaginal bleeding. Do not describe the placental site as “praevia” at this stage- you may tell the woman that most of such placentas are not low-lying by the time she gives birth.

### Amniotic fluid

The deepest vertical pool (cord and limb-free) should be measured at the time of anomaly scan. This should always be recorded on Viewpoint. If this is normal, use the “normal with AFI” function and enter the measurement under “PD”.

### Polyhydramnios: (NEW)

If deepest vertical pool is greater than 8cm, measure the amniotic fluid index (AFI). An AFI greater than 25cm is considered to be polyhydramnios.

- If the AFI is greater than 25cm but less than 30cm, patient should be referred to antenatal clinic.
- If AFI is 30cm or greater, patient should be referred to the fetal medicine unit to be seen within 3 working days.

If polyhydramnios is observed in a woman who is known to be diabetic, she does not need referral to Fetal Medicine. Any referral to Fetal medicine will be decided in the diabetic clinic.

### Oligohydramnios:

If deepest vertical pool is less than 2cm, this is oligohydramnios. The patient should be referred to Maternity Assessment Unit same day for review to exclude ruptured membranes.

### Outcomes of fetal anomaly scan- data entry, diagnosis fields and referrals

Data should be populated in Viewpoint using the DICOM connection.

Press the display centiles function.

Use the anomaly scan chart set: of BPD, HC, AC and FL: 2 to a line and DO NOT create charts of uterine artery Doppler

When entering diagnoses, use only the codes in the diagnoses dropdown menu on Viewpoint. This should only be one of the 3 pre-existing anomaly scan options. This is important for auditing activity and referrals. Any additional comments should only be in the comments section. In each case, a copy of the report must be filed in the woman's health record.

Outcomes of the anomaly scan include:

- I. **No anomaly identified:** Inform the woman. In the Viewpoint report, use the diagnosis function: "anomaly scan - no evidence of fetal abnormality".
  
- II. **Anomaly scan cannot be completed** due to for example (but not confined to)
  - a. Increased maternal body mass index (BMI)
  - b. Maternal body habitus
  - c. Uterine fibroids
  - d. Abdominal scarring
  - e. Sub-optimal fetal position

Record reason for incomplete/inadequate scan in the comments section in Viewpoint and explain to the woman. Use the appropriate diagnosis function e.g. "anomaly - unable to complete - further scan offered". A single further scan should be offered at 23 weeks gestation.



- III. **Anomaly identified or suspected:** Inform the woman of the finding, record finding on report in the comments and use diagnosis field "Anomaly scan- referred to FMU". A referral to FMU is made by completing a FMU referral form which should be faxed or emailed to the specialist midwives. On receipt of a referral, the specialist midwives will allocate an appointment within 3 working days and contact the woman directly. Please ensure all details on the referral are completed correctly as incorrect entries may delay review.

### Outcome of risk assessment for small for gestational age/growth pathway

After the anomaly scan complete the Growth Scan Pathway form to book follow up scans.

There are 4 questions regarding risk. 3 should have been completed before the scan; Q4 (PAPP-A level) will need to be completed by the sonographer (a low PAPP-A result will be flagged up as a message box in Viewpoint at the start of the scan).

These are the possible pathways:

	Risk Factors 	Uterine artery Doppler 		ACTION
Pathway A →	No *risk factors (no boxes ticked yes)	Normal Uterine arteries (total PI <2.5)	Low risk for SGA/PET	36/40 growth scan
Pathway C →	*Risk factors (one or more boxes ticked yes)	Normal Uterine arteries (total PI <2.5)	Med risk for SGA/PET	32/40 and 36/40 growth scans
Pathway D →	*Risk factors (whether ticked or not)	Abnormal Uterine arteries (total PI ≥ 2.5)	High risk for SGA/PET	28/40, 32/40 and 36/40 growth scans Needs to be under Consultant Care. Needs MW/ cons. appointment @25/40 and 31/40 for BP check or if booked under Silver Star, 24/40 SS appointment.
Pathway D →	Dichorionic twin pregnancy (MC twins and high order multiples to FMU)	n/a		28/40, 32/40 and 36/40 growth scans Please arrange usual clinic and scan follow up in the current manner if not already booked

**\*Risk factors:**

- Previous baby <2500g (5lbs 8oz) at any gestation
- Aged 40 or above and nulliparous
- Smoking ≥10 day
- PAPP-A <0.3MoMs

The Growth Scan Pathway form should be used to indicate which scans should be booked. A copy of this should be filed in the hand held notes between the antenatal flowchart and the 'Transfer of Care' yellow tab.

If the woman wishes to have further discussion concerning her risk, particularly if she has abnormal uterine Dopplers, she can be referred to the Wednesday morning Risk Assessment Clinic on Level 6. This clinic is run by Mr Chakravarti.

### **Clinician-determined growth scan pathways**

Please note women at very high risk on the basis of pre-existing medical disease or previous obstetric history will be placed on the appropriate pathway as above and then have any additionally required scans requested by their clinicians, as currently occurs.

These criteria are:

- Previous pregnancy loss at or after 16 weeks
- Pre-existing significant medical disease (such as antiphospholipid syndrome, chronic hypertension requiring treatment etc)

### **Further assessment of fetal size following the anomaly scan (NEW)**

In addition to repeat scans determined according to the SGA/ growth scan pathway the measurements of the baby at the anomaly scan may require earlier follow up. Further scans should not be booked in the USS department but the following action should be taken:

HC, AC, FL all <5<sup>th</sup> centile and EFW <5<sup>th</sup> centile: refer for FMU *review*

HC, AC and FL >5<sup>th</sup> centile but EFW <5<sup>th</sup> centile: no referral required

Any of HC, AC or FL <5<sup>th</sup> centile: refer for FMU *scan review*

Note the *scan review* will usually NOT require the woman to attend FMU in person (see Referral to Fetal Medicine Unit)

### **Referral to Fetal Medicine Unit**

If an abnormality is suspected and a FMU scan is indicated this should be arranged by emailing or faxing a referral. The woman will be rung by the unit to arrange an appointment. Inform the woman of the finding, record finding on report in the comments and use diagnosis field "Anomaly scan - referred to FMU". A referral to FMU is made by completing a FMU referral form which should be faxed or emailed to the specialist midwives. On receipt of a referral, the specialist midwives will allocate an appointment within 3 working days and contact the woman directly. Please ensure all details on the referral are completed correctly as incorrect entries may delay review. In some circumstances the scan images/measurements only will be reviewed and the woman will be rung by a FMU midwife to explain that she does not need to attend in person.

In addition, the sonographer may request that FMU reviews either images or the scan measurements: under these circumstances the woman may not need to attend for a FMU appointment. The diagnosis field "Anomaly scan - referred to FMU" should be used, a

referral should be made in the normal manner, but it should be clear in the relevant boxes on the referral form if 'review of images/ measurements only' is required. You should also indicate whether you wish the woman to be contacted by the unit following this review: this contact should only occur if you have informed the woman you are requesting this review.

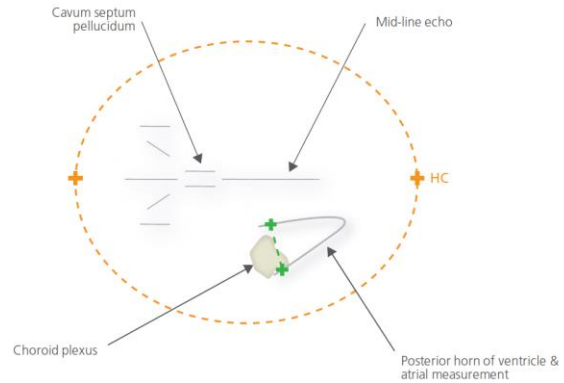
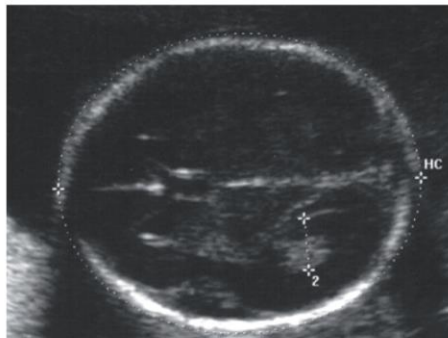
Following FMU review of images/measurements only a comment will usually be added, with the date, in either the comments section of the anomaly scan, or as a message box.

## Appendix 1 – Overview of anatomical views to be assessed at the anomaly scan

Area	Structures assessed	View	Image stored
1 Head & neck	Skull Neck: Skin fold (NF) Brain: <ul style="list-style-type: none"> <li>▪ Cavum septum pellucidum (CSP)</li> <li>▪ Ventricular atrium (Va &amp; Vp)</li> <li>▪ Cisterna magna (CM)</li> <li>▪ Cerebellum (TCD)</li> </ul>	Shape Transventricular view to identify CSP, measure BPD, HC & Vp) Transcerebellar view to measure TCD, CM, NF	Transventricular view Suboccipitobregmatic view for posterior fossa and neck
2 Face	Lips, nostrils Profile	Coronal view to visualise intact lip: view to include nostrils and lips; sagittal view to assess profile	Coronal view of lips and nasal tip
3 Chest	Heart Situs/laterality <ul style="list-style-type: none"> <li>- 4-chamber view</li> <li>- outflow tracts</li> </ul> Lungs	See cardiac protocol- Appendix 3 Determine left and right side of fetus from position of fetus in uterus Transverse section of thorax including complete rib and crux of heart Aorta and left ventricular outflow tract & Pulmonary/right ventricular outflow tract/3VV/3VT Look for any echogenic or cystic areas.	Transverse thoracic - 4-chamber view - outflow tracts
4 Abdomen	Stomach and short intrahepatic section of umbilical vein  Abdominal wall Renal Pelvis Bladder	Transverse; if stomach bubble not visible, ensure it is present by waiting to see it fill. Check early for stomach in exam, if not visible, again at then end. If still not visible, rescan in 30minutes. If still not visible, refer to PND. Transverse (demonstrate intact) Transverse- measure if AP looks increased Transverse	Abdominal circumference showing AC measurement
5 Spine	Vertebrae Skin covering	Sagittal, transverse& coronal Sagittal	Sagittal view of spine including sacrum and skin covering
6 Limbs	Femora Tibia & fibia Humerus Radius/ulna Hands- metacarpals Feet- metatarsals Orientation of feet to lower legs	Both visible; femur length (one leg only) Visible (both legs) Visible (both arms) Visible (both arms) Visible (both hands, not counted) Visible (both feet, not counted) Coronal view to examine for talipes	Femur length (one leg only) demonstrating FL measurement
7 Uterine cavity	Amniotic fluid Placenta		Subjective volume Visible and position noted

## Appendix 2 – Base menu of anatomical images to be stored

### Head circumference and ventricular atrium

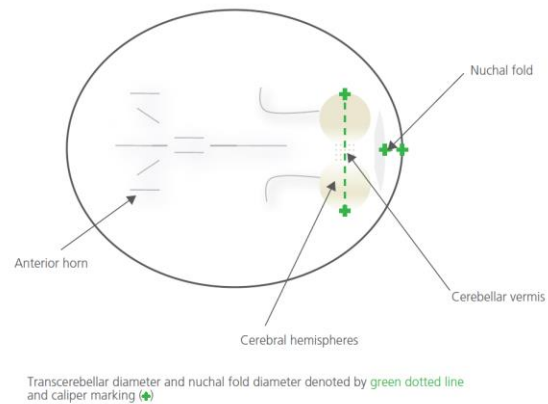
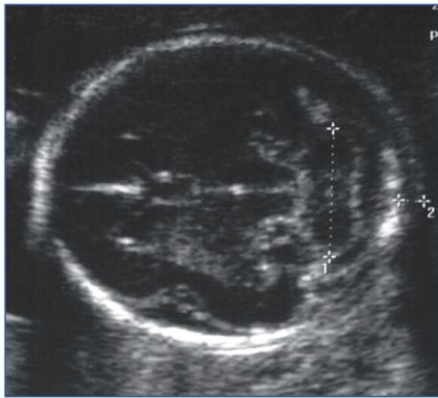


Head circumference denoted by **orange dotted line** and caliper markings (+)  
Ventricular atrial measurement denoted by **green dotted line** and caliper markings (+)

Essential criteria for imaging acquisition (in bold measurements required by FASP):

1. Image should be stored
2. Symmetry: The two hemispheres should be symmetrical
3. Anterior and posterior ventricles should be visible
4. Cavum of the septum pellucidum should be visible
5. No cerebellum should be visualised
6. Ellipse placement should be adequate to the size of the head
7. **HC callipers** placement should be along the outer border of the skull
8. Callipers of the BPD should be placed “outer to outer”
9. **Vp callipers** placement should be “inner to inner” perpendicular to the ventricular cavity
10. Region of interest size should be more than 30% of the total picture size

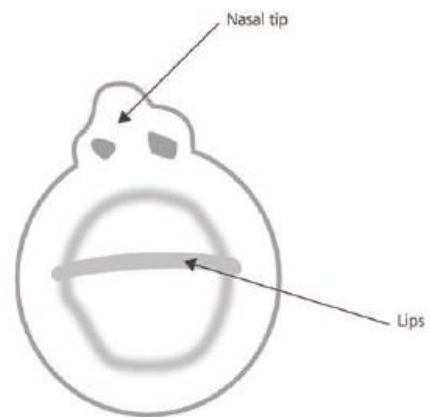
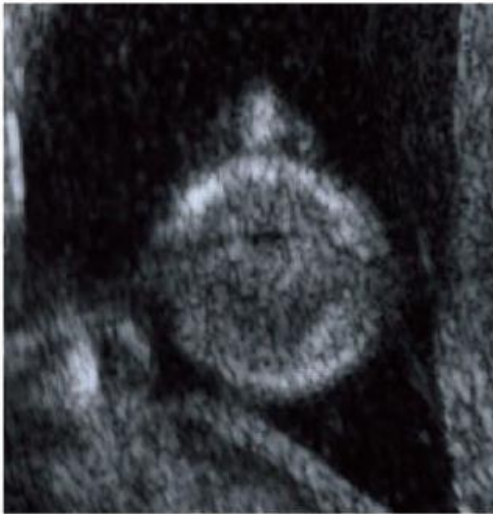**Transcerebellar diameter (TCD) and nuchal fold (NF).**



Essential criteria for imaging acquisition (in bold measurements required by FASP):

1. Image should be stored
2. Symmetry: The two hemispheres should be symmetrical
3. Cerebellum should be visualised at its maximum diameter
4. Cavum of the septum pellucidum should be visible
5. **TCD** callipers placement should be outer to outer the cerebellar hemispheres
6. **CM** callipers should be placed between the cerebellar vermis and the internal side of the occipital bone
7. **NF** calliper placement should be from the outer border of the skull to the outer border of the skin
8. Region of interest size should be more than 30% of the total picture size

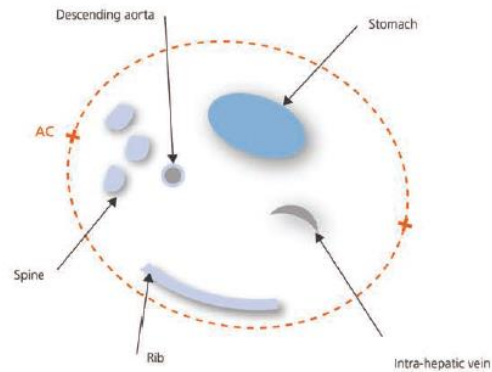
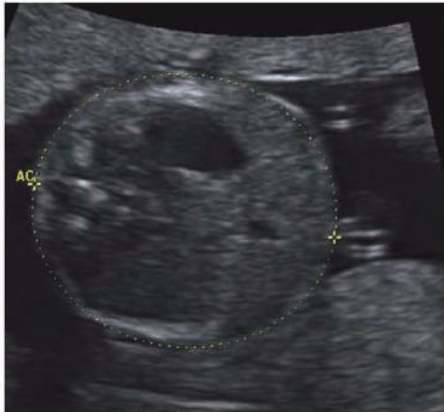## Nasal tip and lips



Essential criteria for imaging acquisition:

1. Image should be stored
2. Upper lip visible
3. Two nostrils visible
4. Two lip angles visible
5. Region of interest size should be more than 30% of the total picture size

## Abdominal circumference




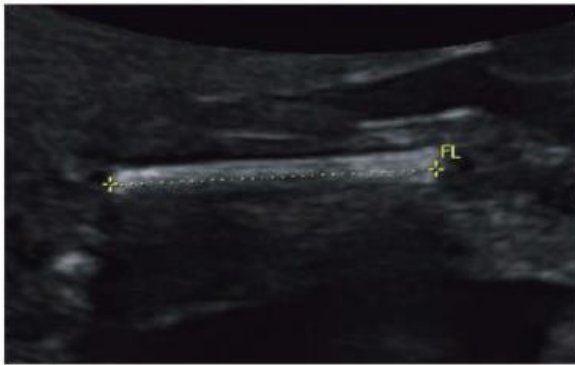
Abdominal circumference denoted by orange dotted line and calliper markings (+)

Essential criteria for imaging acquisition (in bold measurements required by FASP):

1. Image should be stored
2. AC should be as circular as possible
3. Stomach bubble visible
4. Umbilical vein anterior 1/3<sup>rd</sup> and level of portal sinus
5. No kidney present
6. Single straight rib
7. **AC** calliper placement on the outer border of the skin
8. Region of interest size should be more than 30% of the total picture size

Note: If the stomach is not visible, please ensure that it is present by waiting to see it fill. Check for it early in your examination and if not visible, again at the end. If still not visible rescan in approximately 30 minutes. If still not visible, refer to FMU.

## Femur Length

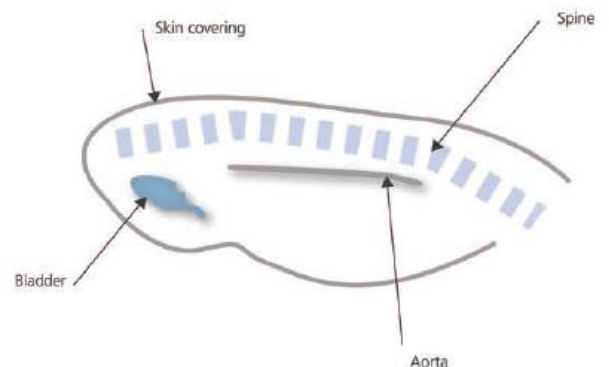
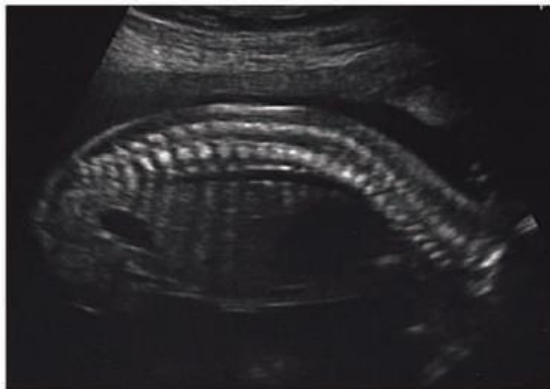

Femur length denoted by green dotted line and caliper markings (+)

Essential criteria for imaging acquisition (in bold measurements required by FASP):

1. Image should be stored
2. Ends of the femur clearly visible
3. Angle of the femur less than 45 degrees to the ultrasound beam
4. **FL** callipers placed outer to outer in the middle of the femur extremities
5. Region of interest size should be more than 30% of the total picture size

## Longitudinal view of spine



Essential criteria for imaging acquisition (in bold measurements required by FASP):

1. Image should be stored
2. Dorsal spine visible
3. Sacrum visible
4. Alignment of vertebrae visible from the dorsal level to the sacrum
5. Continuity of skin line
6. Amniotic fluid visible beyond skin dorsally
7. Region of interest size should be more than 30% of the total picture size

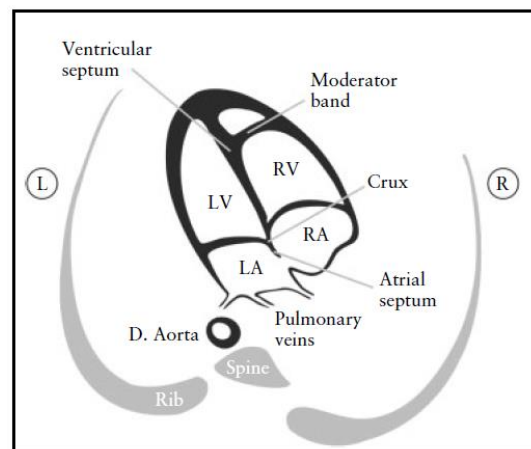
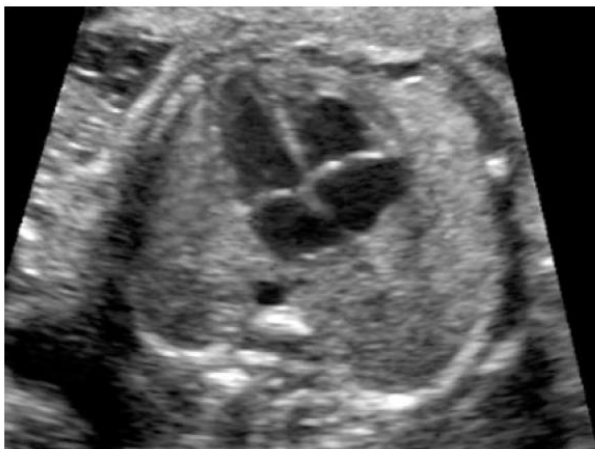## Appendix 3 – Fetal cardiac anomaly scan

Cardiac images are ideally stored as cine clips.

As part of basic fetal echocardiography, situs/laterality, heart size, heart rate and rhythm must be examined. Fetal cardiac anomaly scanning should also assess:

1. Four chamber view of heart
2. Aorta/Left ventricular outflow tract
3. Pulmonary/Right ventricular outflow tract OR Three vessel (pulmonary artery, aorta, superior vena cava) view

### Four chamber view



(from Carvalho et al, 2013)

#### Assessment of fetal situs/laterality and the four chamber view

##### Situs and general aspects

- Fetal laterality (identify right and left sides of fetus)
- Stomach and heart on left
- Heart occupies a third of thoracic area
- Majority of heart in left chest
- Cardiac axis (apex) points to left by  $45^{\circ} \pm 20^{\circ}$
- Four chambers present
- Regular cardiac rhythm
- Pericardial effusion not larger than 2mm

##### Atrial chambers

- Two atria, approximately equal in size
- Foramen ovale flap in left atrium
- Atrial septum primum present (near to crux)
- Pulmonary veins (at least 2) entering left atrium

##### Ventricular chambers

- Two ventricles, approximately equal in size
- No ventricular wall hypertrophy
- Moderator band at right ventricular apex
- Ventricular septum intact (apex to crux)

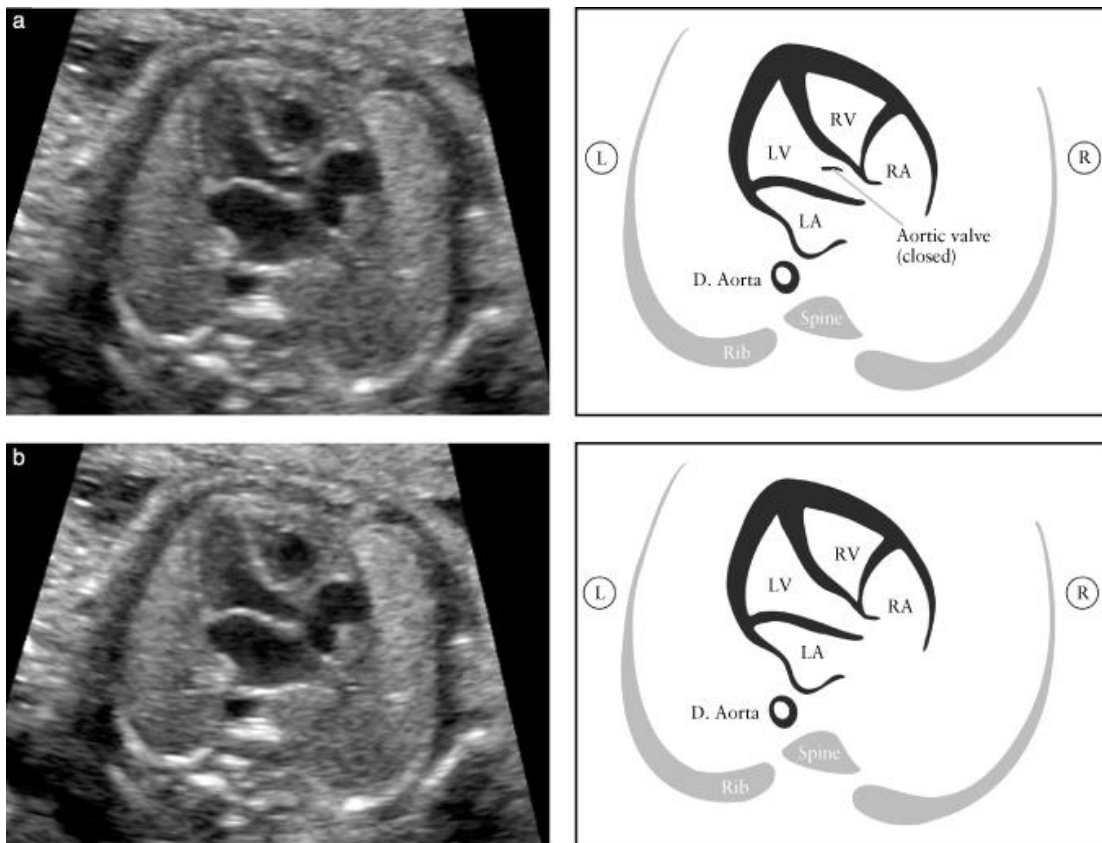
##### Atrioventricular junction and valves

- Intact cardiac crux
- Two atrioventricular valves open and move freely
- Differential offsetting: tricuspid valve leaflet inserts on ventricular septum closer to cardiac apex than does mitral valve and allows identification of the right ventricle

### Outflow tract views

In assessment of the LVOT and RVOT, it is important to ascertain normality of the two great vessels, including their connection to the appropriate ventricles, their relative size and position and adequate opening of their arterial valves. If any of these features appear abnormal, referral to fetal cardiology should be made using standard PND/FMU referral form. A normal examination requires that the great vessels are approximately equal in size (PA very slightly larger) and cross each other at right angles from their origins as they exit from the respective ventricles (normal “cross-over”).

### Left ventricular outflow tract

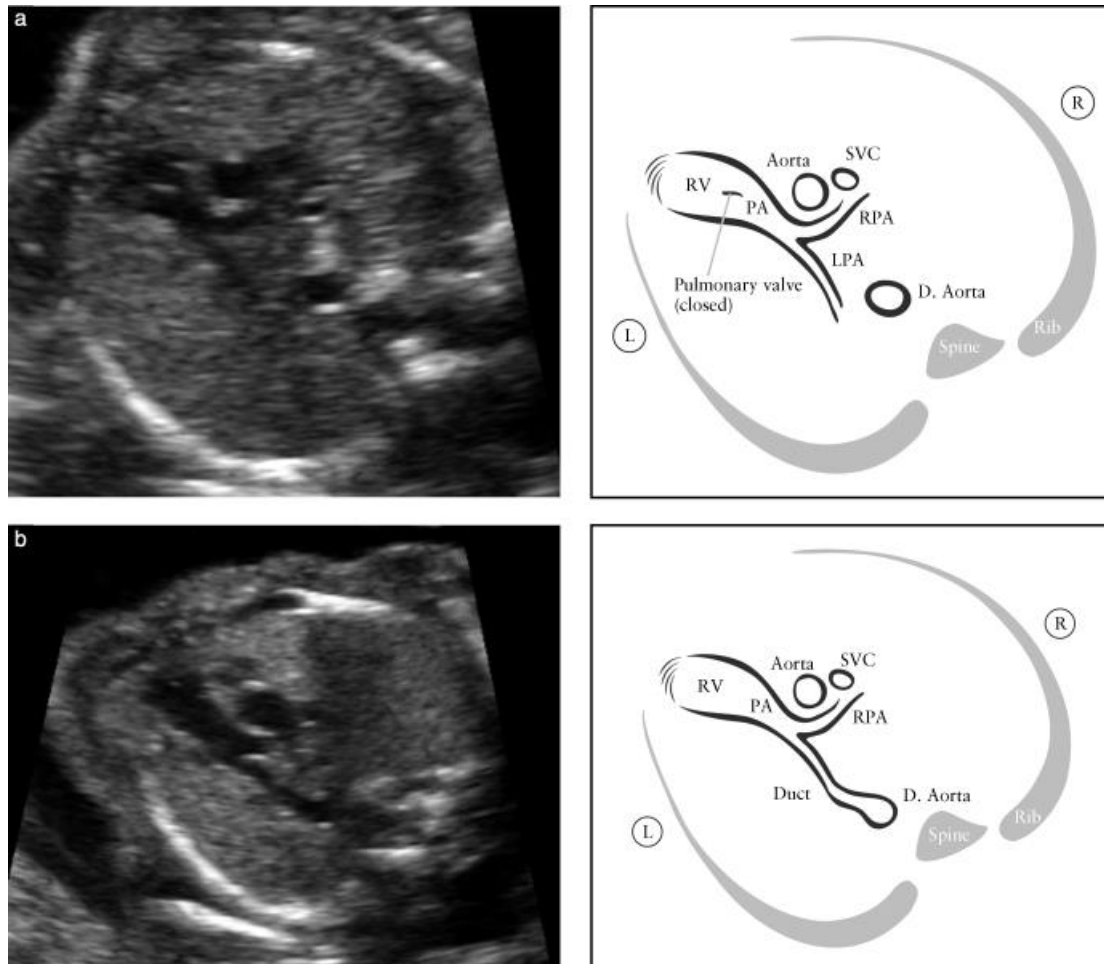


(from Carvalho et al., 2013)

The LVOT view demonstrates a vessel connected to the left ventricle. A normal LVOT will demonstrate continuity between the interventricular septum and the anterior wall of this vessel, which in the normal heart corresponds to the aorta (identified by head and neck vessels arising from it). The aortic valve should not be thickened and should open freely.

A LVOT view must be stored as part of the fetal cardiac anomaly scan. The valve is closed in (a) and open in (b) – a cine loop will show both, either view would be acceptable as a frozen image.

### Right ventricular outflow tract

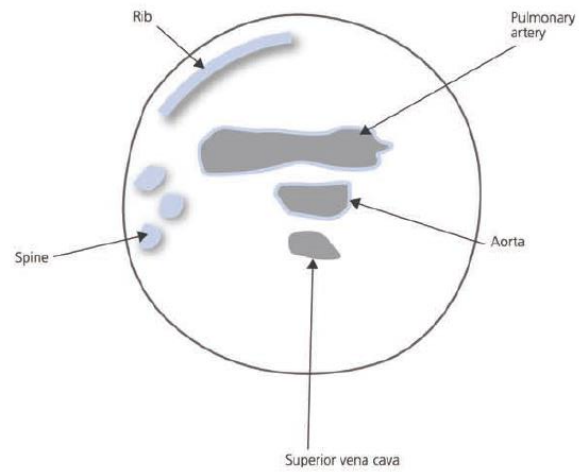
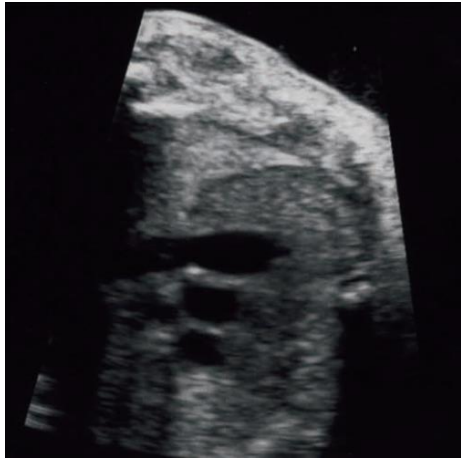

(from Carvalho et al, 2013)

This view shows a vessel connected to the morphological right ventricle (RV). This vessel divides early thereby identifying it as the pulmonary artery. The pulmonary artery is slightly larger than the aorta which it crosses at almost right angles. The pulmonary artery divides into right and left branches and then continues posteriorly as the ductus arteriosus to join the artery just after its third head/neck branch. The pulmonary valve should not be thickened and should open freely. In (a) the bifurcation of the PA into both pulmonary arteries can be seen.

A RVOT view must be stored as part of the fetal cardiac anomaly scan. The valve is closed in (a) and open in (b) – a cine clip is preferred but either view would be acceptable as a stored image.

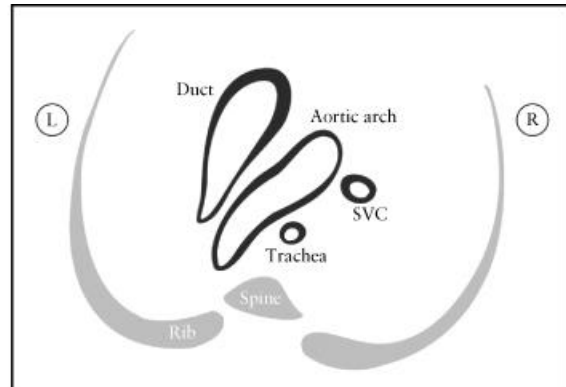
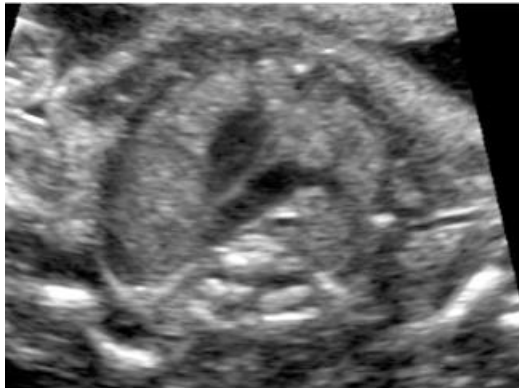### Three vessel view (3VV)



The 3VV view best demonstrates the relationship between the pulmonary artery, aorta and superior vena cava (SVC) in the upper mediastinum. It is important to note the correct position and alignment of the 3 vessels as well as their relative size. The pulmonary artery, to the left, is the largest of the three and the most anterior, whereas the SVC is the smallest and most posterior.

### Three vessel view and trachea view (3VT)

A 3VT view must be stored as part of the fetal cardiac anomaly scan. A cine clip is preferred but a stored image would be acceptable.



The trachea is usually identified as a hyperechogenic ring surrounding a small fluid-filled space. This view best demonstrates the transverse aortic arch and its relationship with the trachea. In the normal heart, both the aortic arch and the ductal arch are located to the left of the trachea, in a "V"-shaped formation.

## Appendix 4 – Uterine artery Doppler

The purpose of this guidance is to standardise and optimise the technique of Doppler signal acquisition. Poor acquisition reduces the effectiveness of the screening test and creates work for others.

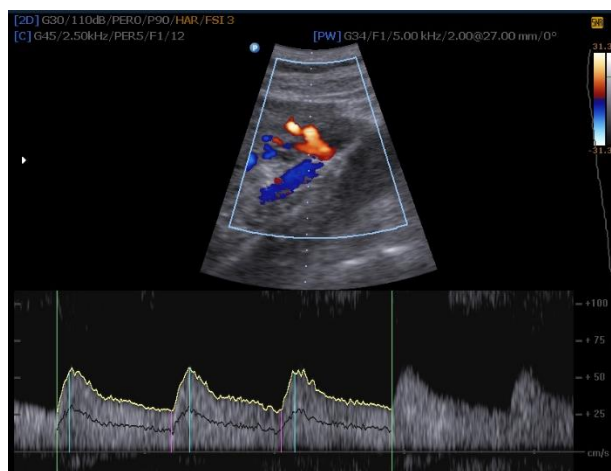
### Obtaining optimum measurements

The UtA Doppler signal should be obtained at the apparent crossover with the external iliac artery using Color Doppler. If the correct anatomic site cannot be identified the UtA tract closest to the iliac artery should be insonated.

In case of an early bifurcation of the UtA the larger vessel should be insonated. The uterine artery will always have a velocity of  $>45\text{cm/sec}$ . If the velocity is less you may be insonating an arcuate vessel.

In rare cases there is only one vessel because of a uterine abnormality. If only one vessel can be insonated a PI of  $\geq 1.25$  should be considered high risk and the patient managed as the total PI was  $\geq 2.5$ .

### Normal uterine artery



Once 4-6 cycles are obtained and frozen, press the 'uterine artery' (left or right) option, then Autotrace. Limit the section autotraced to the best 3 consecutive similar waveforms. In case excessive background noise and signal is poor, a manual trace can be used. Store the best image of both sides. Use the 'send report' function to ensure they are stored in Viewpoint; in the event of a lost connection, manually enter both PI and RI for each side.

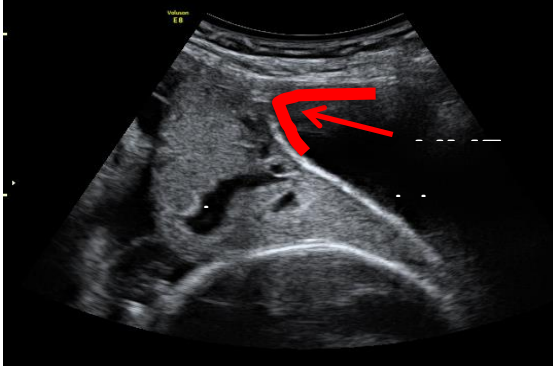
The following 6 criteria must be satisfied for any of the Doppler measurements obtained.

Magnification	50% of the screen (zoom box) and sample gate in centre of vessel
---------------	--

Angle	less than 30%
Sweep speed	4 - 6 waves insonated with constant signal
Clearance of the IMAGE	Velocity and colour gain correction (no veins signal)
Anatomic Site	UtA: before the bifurcation above the iliac vessels
Velocity Scale	75% of the peak systolic velocity

## Appendix 5 – Placental site assessment

In this image the placenta is not clearly low, but is under the uterovesical fold (UVF), which is marked by the red arrow. This is only significant if the woman has had previous uterine surgery.



## Appendix 6 – Monitoring and compliance

<b>Compliance Standard</b>	<b>Monitoring method</b>	<b>Frequency of monitoring</b>	<b>Review Group/Committee</b>
Storage of 6 base menu anatomical views of adequate quality	Audit using validated tool to assess 3 randomly scan examinations undertaken by each sonographer	6 monthly	MCGC
Storage of 3 cardiac views of adequate quality	Audit using validated tool to assess 3 randomly scan examinations undertaken by each sonographer	6 monthly	MCGC
Storage of 3 adequate uterine artery images	Audit using validated tool to assess 3 randomly scan examinations undertaken by each sonographer	6 monthly	AHSN team
Uterine arteries measured	Viewpoint analysis	6 monthly	AHSN team

## References

NHS Fetal Anomaly Screening Programme (2010). 18+0 to 20+6 weeks fetal anomaly scan national standards and guidance for England.

<http://fetalanomaly.screening.nhs.uk/standardsandpolicies>

Carvalho JS et al., ISUOG Practice Guidelines (updated): sonographic screening examination of the fetal heart. *Ultrasound Obstet Gynecol* (2013); **41**: 348–359

[http://www.isuog.org/NR/rdonlyres/14895030-9283-4DB6-9CF7-BF9304DAB0B5/0/ISUOG\\_cardiac\\_screening\\_guidelines\\_aspublished\\_2013.pdf](http://www.isuog.org/NR/rdonlyres/14895030-9283-4DB6-9CF7-BF9304DAB0B5/0/ISUOG_cardiac_screening_guidelines_aspublished_2013.pdf)

## Further resources/training

Fetal Medicine Foundation Online Education: Fetal echocardiography

<https://fetalmedicine.org/fetal-echocardiography-1>

Tiny Tickers

<http://www.tinytickers.org/content/resources>

Practice Guidelines for performance of the routine mid-trimester fetal ultrasound scan. *Ultrasound Obstet Gynecol* (2011); **37**: 116-126

<http://www.isuog.org/NR/rdonlyres/EA865840-6CA3-45AC-9E99-FBAF775119A9/0/ISUOGGuidelinesmidtriscan20101210.pdf>

Papageorghiou AT et al (2013) International Fetal and Newborn Growth Consortium for the 21st Century. Ultrasound methodology used to construct the fetal growth standards in the INTERGROWTH-21st Project. *BJOG*; **120** Suppl 2:27-32.